



ORIGINAL ARTICLE

## Benefits of medially based perichondrio-adipo-dermal flap in cartilage sparing prominent ear surgery<sup>☆</sup>

Yasser Mohammed Mandour<sup>a,\*</sup>, Ayman M. Abdelmofeed<sup>b,c</sup>

<sup>a</sup> Faculty of Medicine, Department of Otorhinolaryngology, Benha University, Egypt

<sup>b</sup> Department of General Surgery, Plastic Surgery Unit, Benha University, Egypt

<sup>c</sup> Benha Faculty of Medicine, Benha, Egypt

Received 5 July 2021; accepted 15 September 2021

### KEYWORDS

Otoplasty;  
Perichondrio-adipo-  
dermal flap;  
Prominent ear

### Abstract

**Background:** Cartilage-cutting and cartilage-sparing techniques are the two types of otoplasty procedures. Because of the significant risk of haematoma, skin necrosis, and ear deformity, cartilage-cutting techniques have been questioned. As a result; suture-based cartilage-sparing procedures such as Mustarde and Furnas suture procedures have grown in popularity. However, these techniques have a tendency for deformity recurrence due to cartilage memory and suture fatigue, as well as the possibility of suture extrusion and pinpricking sensation of the sutures.

**Methods:** In this study, we used a medially based adipo-dermal flap including perichondrium which is elevated from the back of the auricle to cover and support a cartilage-sparing otoplasty, thirty-four patients (14 female and 20 male) were operated using this technique. The medially based perichondrio-adipo-dermal flap is advanced anteriorly and fixed to the helical rim under cover of the distal skin flap. This procedure sought to cover the suture line preventing suture extrusion and support in the repair of the deformity preventing its recurrence.

**Results:** The average operative time was 80 min, ranging from 65 to 110 min. The patients passed the early postoperative period uneventfully except for 2 patients; one patient (2.9%) developed haematoma, and the other patient developed a small area of necrosis on the new antihelical fold. In late the postoperative period recurrence of the deformity developed in one patient. No patients developed suture extrusion or granuloma.

**Conclusion:** The treatment to repair prominent ears is easy and safe, with benefits such as a natural-looking antihelical fold and minimal tissue stress. The medially or proximally based adipo-dermal flap may help to lower recurrence rates and suture extrusion.

© 2021 Sociedad Española de Otorrinolaringología y Cirugía de Cabeza y Cuello. Published by Elsevier España, S.L.U. All rights reserved.

<sup>☆</sup> We certify that we are the author of this article and all the data in this article not published elsewhere. We would like to publish this work in your respectable journal and transfer the copy write of this work to your respectable journal. We hope to accept this work to be published in your journal. We will work as corresponding author for this work and we will grantee to answer all your questions.

\* Corresponding author.

E-mail address: [ghader\\_massoud@yahoo.com](mailto:ghader_massoud@yahoo.com) (Y.M. Mandour).

<https://doi.org/10.1016/j.otorri.2021.09.003>

0001-6519/© 2021 Sociedad Española de Otorrinolaringología y Cirugía de Cabeza y Cuello. Published by Elsevier España, S.L.U. All rights reserved.

Please cite this article as: Y.M. Mandour and A.M. Abdelmofeed, Benefits of medially based perichondrio-adipo-dermal flap in cartilage sparing prominent ear surgery, Acta Otorrinolaringológica Española, <https://doi.org/10.1016/j.otorri.2021.09.003>

**PALABRAS CLAVE**

Otoplastia;  
Colgajo de  
pericondrio-adipo-  
dérmico;  
Oreja prominente

**Ventajas del colgajo pericondrial-adipo-dérmico con base medial en la cirugía de remodelación del cartílago de oreja prominente**

**Resumen**

*Antecedentes:* El recorte y la remodelación del cartílago son los dos tipos de técnicas en los procedimientos de otoplastia. Debido al riesgo considerable de hematoma, necrosis cutánea y deformidad de la oreja, las técnicas de recorte del cartílago han sido cuestionadas. Como resultado, los procedimientos de remodelación del cartílago basados en sutura, tales como las técnicas de Mustarde y de Furnas, han ganado popularidad. Sin embargo, dichas técnicas tienden a recidivar la deformidad debido a la memoria del cartílago y a la fatiga de la sutura, así como hay la posibilidad de extrusión y de la sensación de pinchazo en ellas.

*Métodos:* En el presente estudio utilizamos un colgajo pericondrial-adipo-dérmico con base medial que se eleva desde el dorso auricular para cubrir y soportar la otoplastia de remodelación del cartílago, habiendo operado a 34 pacientes con esta técnica (14 mujeres y 20 varones). El colgajo pericondrial-adipo-dérmico con base medial se avanza anteriormente y se fija al borde helical inferior para cubrir el colgajo cutáneo distal. El objetivo de este procedimiento fue cubrir la línea de la sutura, impidiendo la extrusión de la misma, y soportar la reparación de la deformidad previniendo su recidiva.

*Resultados:* El tiempo quirúrgico medio fue de 80 min, fluctuando de 65 a 110 min, transcurriendo el periodo postoperatorio temprano de los pacientes con normalidad, excepto en dos pacientes: uno de ellos (2,9%) desarrolló hematoma y el otro desarrolló una zona pequeña de necrosis en el nuevo pliegue antihelical. En el periodo postoperatorio posterior un paciente desarrolló recidiva de la deformidad. Ningún paciente desarrolló extrusión de la sutura ni granuloma.

*Conclusión:* El tratamiento reparador de las orejas prominentes es fácil y seguro, con beneficios tales como el aspecto natural del pliegue antihelical y el estrés tisular mínimo. El colgajo adipo-dérmico con base medial o proximal puede ayudar a conseguir menores tasas de recidiva y de extrusión de la sutura.

© 2021 Sociedad Española de Otorrinolaringología y Cirugía de Cabeza y Cuello. Publicado por Elsevier España, S.L.U. Todos los derechos reservados.

**Introduction**

Auricle of ear is defined as prominent when it protrudes more than 20 mm and the angle between ear and scalp greater than 35°. <sup>1</sup> Prominent auricle is a relatively common condition, with autosomal dominant inheritance. <sup>2</sup> Conchal hypertrophy, failure of antithetical folding, a wide angle between the concha and mastoid bone, lobule prominence, and a combination of these factors contribute to the prominent ear. <sup>3</sup>

Anthropometric measurements define it as having a conchoscaphal angle of 90 or greater, a conchomastoid angle greater than 30, an increase in height (normally 5–7 cm) and width (normally 50–60 percent of height), and increased helical rim distances from the scalp (normally 1–1.2 cm at the upper part, 1.6–1.8 cm at the middle part and 2–2.2 cm at the lower part). <sup>4</sup>

Because the auricle develops rapidly after birth, with 85 percent of vertical ear growth occurring by the third year of life and 90 percent of adult width occurring within the first year of life, vertical growth reaching 93 percent and width reaching 97–99 percent by 10 years of age, most procedures are performed between the ages of 5 and 7 years. <sup>5</sup>

The goals of prominent ear correction are to define the antihelix and reduce the conchoscaphal and conchomastoid

angles, as well as conchal hypertrophy. The upper part of the auricle protrusions must be fixed since the helix of both ears should be seen beyond the antihelix from the front view. A smooth antihelical fold should be achieved, rather than a harsh antihelical fold. <sup>6</sup>

The surgical management of prominent ear categorized into: cartilage cutting and cartilage sparing methods. <sup>7</sup> Complications from cartilage cutting techniques include cartilage weakening, cartilage disruption due to scar contracture, hematoma from wide dissection, and asymmetry. <sup>8</sup>

Cartilage sparing techniques include cartilage (molding, scoring, suturing, fixation) and skin reduction or a combination of these techniques. However, these techniques have the tendency for deformity recurrence due to cartilage memory and suture fatigue, as well as the possibility of suture extrusion and pinpricking sensation of the sutures. <sup>9</sup>

Because there are so many various ways, no single ideal solution has been generally acknowledged. Horlock et al., who utilized a postauricular fascial flap to cover Mustarde and Furnas type permanent sutures to lower suture extrusion, have aroused interest in suture procedures. <sup>10</sup> Also others used special suture material as expanded polytetrafluorethylene (GORE-TEX, W. L. Gore & Associates) to

decrease the chance for suture extrusion especially in recurrent cases.<sup>10</sup>

In our research, we'll use a medially based flap made up of three layers for durability: perichondrium, subcutaneous adipose tissue, and dermis. We hope to achieve the following goals with the use of the medially based perichondrio-adipo-dermal flap: create a natural-looking antihelical fold with no sharp edges; decrease both the conchomastoid and conchoscaphal angles; achieve long-lasting results with no complications; and eliminate the suture extrusion problem seen with traditional suture-based cartilage sparing techniques, by covering the repair with a well vascularized medially based dermal flap which covers and supports the suture material

## Patients and methods

From January 2018 to July 2020, thirty-four patients (14 female and 20 male) underwent bilateral prominent ear deformity correction otoplasties at Benha University Hospital by the same group of surgeons and using the same technique, following approval from the local ethical committee and full informed consent from all patients to be included in the study for surgical technique, follow-up period and photographing.

The patients' ages ranged from 8 to 32 years, with a mean age of 19.5 years. Operations were done under general anesthesia on all patients.

Measurements of distances between auricle and mastoid, and conchomastoid angle were taken preoperative and 6 months postoperative. The mean distance from the most protruding point of the helix to the mastoid bone was measured as 29.11 mm, and the mean conchomastoid angle, measured with a goniometer, was 46.8°.

Patients were photographed from six different perspectives: front, back, right, left, right oblique, and left oblique.

Only Mustarde and Furnas suturing methods were used to correct the prominence of the ears. No cartilage-cutting techniques were used, with the addition of medially based perichondrio-adipodermal flap technique to cover the suture line of the cartilage and support setting back the auricle with this medially based well vascularized perichondrio-adipodermal flap in which the pedicle is continuous with the stem of post auricular vessels, so this ensured a good vascularity of the flap. Fifteen Patients from 34 had conchae hypertrophy requiring partial conchal resection.

## Surgical technique

Gentle pressure is applied to the helix toward the mastoid region, as in any other popular ear correction operation, and the newly shaped antihelical fold is marked.

With the patient under general anesthesia, a small ellipse was marked on the posterior auricular skin and then infiltrated with lidocaine and epinephrine at a concentration of 1:200,000. The marked elliptical skin area then was deepithelialized. From the superior margin of the elliptical area then the dermal flap was incised deep to the perichondrium and the perichondrio-adipodermal flap was elevated from lateral to medial fashion in the subperichondrial plane to prepare the medially based perichondrio-adipodermal

flap. Dissection was continued toward the mastoid fascia. Depending on the characteristics of the deformity, the conchoscaphal sutures (Mustarde) to define the antihelix, the conchomastoid sutures (Furnas) to support the setback of the ear, conchal resection if there is conchal hypertrophy, lobule fixation if prominent.

The posterior surface of the conchal cartilage is weakened by scoring with the help of a number 11 blade. This scoring procedure in adult patients results in a lesser cartilage resistance during the sit back of the flap to the mastoid area to give its latest form. Because of presence of a thin and soft cartilage, scoring is not applied in child patients.

For reshaping of the auricular cartilage, 3-0 and 4-0 polypropylene permanent monofilament suture was used in unequal transverse mattress sutures (the distal suture bite more than proximal one to help bending of the antihelix in a smooth curved fashion not in straight fashion if taken equal) After reshaping of the auricular cartilage, the flap was sutured to the cartilage at the helical rim above suture line by three 4-0 polyglecaprone sutures. The posterior auricular skin incision was repaired with 4-0 polyglecaprone sutures. A bulky bandage was used to cover the ears, and a head bandage was applied over the dressing. The dressing was changed 24 h after the operation. The head bandage was used for 3 weeks continuously and then for another 3 weeks at night. All the patients received injection antibiotic for 5 days then oral antibiotic for another 5 days.

On the first postoperative day, the dressing was replaced before discharging the patient for quick evaluation. The dressings, packing, and sutures were removed on postoperative Day 10.

Patients will be evaluated for hematomas, ecchymosis, skin necrosis, infections, or wound dehiscence in the early postoperative period, and for suture extrusion, granuloma formation, stitch sinus, asymmetry, scar complications, or relapse of the deformity documented by distance measurements between auricle and skull, concho-mastoid angle in the late postoperative period 1, 3, 6 months.

Patient's satisfaction will be assessed using a modified Laberge et al scoring system. This is a questionnaire for patients or their parents after six months post-surgery its items are as follow:

1. aches when ear is touched.
2. auricular sensations.
3. skin irritation.
4. symmetrical ears.
5. ear shape.

Each item will have responses from 1 to 4. The summation of the points divides the result into four groups; we consider score 20 as very satisfied, 12–19 is considered to be satisfied and 8–11 means dissatisfied while a response less than 8 is considered to be very dissatisfied.<sup>13</sup>

## Statistical analysis

The obtained data were expressed as means  $\pm$  SD, ranges, numbers and percentages. Statistical analysis was conducted using One-way Analysis of Variance (ANOVA test) or Wilcoxon Ranked Test for Unrelated Data (Z test). Possible

**Table 1** Early complications.

	Number of patients	Percentage (%)
<i>Early complications</i>		
Hematomas	1	2.9%
Dehiscence	0	0
Infection	1	2.9%
Necrosis	1	2.9%
Total	2	5.8%
<i>Late complications</i>		
Suture extrusion and pinpricking sensation of sutures	0	0
Irregular antihelix	2	5.8%
Asymmetry	4	11.7%
Recurrence	1	2.9%
Scar hypertrophy or keloid	3	8.8%
Hypersensitivity	2	5.8%

correlations were conducted using Pearson’s correlation coefficient. Statistical analysis was performed using the SPSS program (Version 10, 2002) and the *p* value was considered significant if less than 0.05.

**Results**

From January 2018 to July 2020, thirty-four patients (14 female and 20 male) underwent otoplasty for bilateral prominent ear deformity correction at Benha university hospital. The patients’ ages ranged from 8 to 32 years, with a mean age of 19.5 years. The average age in adult was 28 years, and the average age in children was 10 years. The primary causes of prominent ears were a combination of bilateral hypertrophied, deep conchae in 14 patients (41.2%) and underdeveloped antihelix in 16 patients (47.1%), resulting in a wide distance between auricle and mastoid with wide conchoscaphal and conchomastoid angles or

combinations of deep concha and underdeveloped antihelix in 4 patients (11.7%). Prominent earlobes in five patients (14.7%). Prominent ears were bilateral in all patients.

The average operative time was 80min ranged from 65–110min.

Patients passed the early postoperative period uneventfully except for 3 patients. One patient (2.9%) developed hematoma which was diagnosed on the first postoperative day. The dressing was removed, the wound was explored, and the hematoma was evacuated. The wound was closed again, and the ear was packed and dressed again. The other patient developed a small area of necrosis on the new antihelical fold, which was conservatively managed by debridement and healed by 2ry intention, lastly one case developed superficial infection treated by appropriate antibiotic according to culture and sensitivity, all complications summarized in [Table 1](#).

No stitch sinus or extrusion of threads from wound or skin.

As regard late postoperative data asymmetrical ears were noticed in 4 (5.8%) patients that needed redo in 2(2.9%) patients and elliptical retroauricular skin excision in 2 (2.9%) patients, redo surgery summarized in [Table 2](#)

In addition, two patients (2.9%) developed antihelix irregularities with sharp edges that were rasped. Two patients reported significant ear hypersensitivity over 4 months and one patient developed recurrence in one side after 6 months requiring redo surgery.

No late postoperative suture extrusions or pinpricking sensation of the suture.

Results of patients’ satisfaction are summarized in [Table 3](#) by using modified Laberge et al scoring system. The questionnaire was done revealing that pain when the ear was touched was present in 5 cases (14.7 percent), hypoesthesia in 2 cases (5.8 percent), occasional cutaneous irritation in 2 cases (5.8 percent), asymmetry in 4 cases (11.7 percent), and abnormal ear shape in 2 cases (5.8 percent). Comparing preoperative and postoperative status revealed a significant difference in aesthetic outcome (*p*-value < 0.05), with a higher overall percentage of very satisfied patients or

**Table 2** Redo surgery.

Number of cases	Cause of redo	What done
2 cases	Asymmetry	Complete redo
2 cases	Skin redundancy	Skin excision
2 cases	Sharp antihelix	Rasping
One case	Unilateral complete recurrence of the deformity	Complete redo

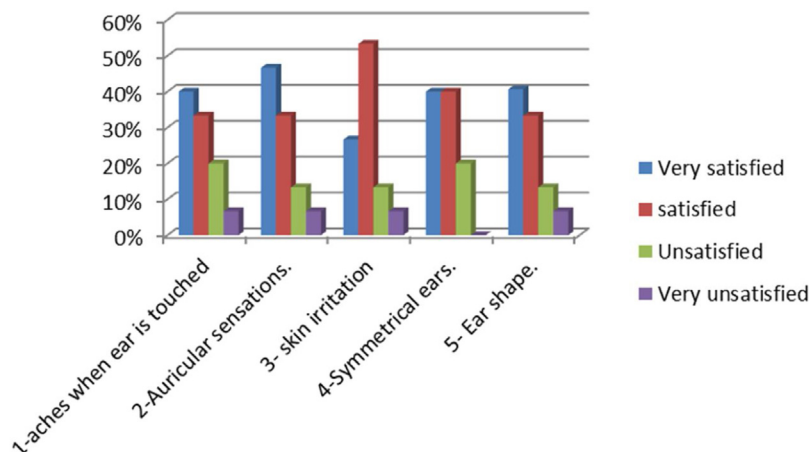
**Table 3** Laberge scale of patient satisfaction.

Likert scale	Very satisfied	Satisfied	Unsatisfied	Very unsatisfied	<i>p</i> -Value
1-Aches when ear is touched	(40%)	(33.33%)	(20%)	(6.67%)	0.014
2-Auricular sensations	(46.67%)	(33.33%)	(13.33%)	(6.67%)	0.028
3-Skin irritation	(26.67%)	(53.33%)	(13.33%)	(6.67%)	0.019
4-Symmetrical ears	(40%)	(40%)	(28%)	(2%)	0.011
5-Ear shape	(46.67%)	(33.33%)	(13.33%)	(6.67%)	0.028

children's parents in comparison to the preoperative condition.

strategy.<sup>7</sup> Additional issues with this approach include suture erosion, extrusion, and granuloma formation over the suture lines, as well as pain from buried sutures.<sup>7,15</sup>

### Diagram of Laberge scale of patient satisfaction



The diagram shows the results of the Likert scale of patient satisfaction. The postoperative assessment after 6 months revealed that the mean distance between the most protruding point of the helical rim and the mastoid area was 17.22 mm, and the mean concha-mastoid angle was 25.6. A significant improvement was observed between the preoperative helix-mastoid distance and the postoperative 6-month helix-mastoid distance ( $p < 0.001$ ), as well as between the preoperative concha-mastoid angle degree and the postoperative 6-month concha-mastoid angle degree ( $p < 0.006$ ) of the patients, the measurements are summarized in Table 4.

To achieve some level of objective assessment a topographic scale was used to evaluate pre and postoperative results. Each patient underwent a photographic assessment before and after surgery at each visit. The photos of before and after were assessed by three surgeons who were not involved with the patients, surgeon-assessed result was evaluated in a visual analog scale (VAS) (scale 0–10 where 0 is worst outcome and 10 is the best). The VAS considered symmetry, scarring and natural appearance. Data provided by surgeons were grouped (Figs. 1–4).

## Discussion

More than 200 distinct procedures have been recorded since the initial aesthetic repair of large ears in 1881.<sup>4</sup>

There are two types of operative techniques: cartilage cutting and cartilage sparing, because of wound contraction and cartilage remodeling, the cartilage cutting approach may cause irreparable ear distortion.<sup>11</sup>

Anterior skin necrosis, cartilage abnormalities, sharp edges, and overcorrection are all possible drawbacks of cartilage cutting methods. Correction of these issues may be more complex and may necessitate additional changes.<sup>11,12</sup>

The cartilage-sparing procedure relies mostly on the installation of permanent sutures to reshape cartilage. Mustarde and Furnas otoplasties are the most common.<sup>13,14</sup>

Aside from the its benefits, the cartilage sparing approach may cause difficulties as some authors have recorded recurrence rates of up to 24% when employing this

Because they cause less damage to the cartilage, otoplasty procedures that protect the cartilage are regarded to be safer. Conversely, when compared to cartilage-cutting techniques, cartilage-sparing techniques have exhibited unacceptable recurrence rates.<sup>7</sup> All of these issues highlight the need to develop cartilage protection techniques.<sup>16,17</sup>

Because the adipo-dermal flap is sutured to the helix distally and continuous with the mastoid fascia, the strain caused when the ear is moved toward the back can spread over the entire flap instead of the three sutures utilized in the Mustarde approach. Regarding this, the resistant force of the cartilage structure applied to any part of the flap that ensures the fixated position of the ear is less.

The dermal flap supports setting back of the ear, which can correct both the conchomastoid and the conchoscapular angles.

Medially based perichondrio-adipo-dermal flap has an advantage over the distally based done by Salih et al.<sup>18</sup> one in its continuity with the stem of post auricular vessels so ensuring its vascularity but the distally based one considered random flap with a questionable random blood supply and survival, also the medially based flap we strip perichondrium from the excised skin island site exposing the conchal cartilage which may be removed or set back so not endangered but the laterally based flap may strip perichondrium from the future antihelix site and may extend to scapha and helix rim.

We saw that the new antihelix was natural looking, round, and smooth in shape in all of the patients who had prominent ear deformity repaired using the medially based perichondrio-adipo-dermal flap.

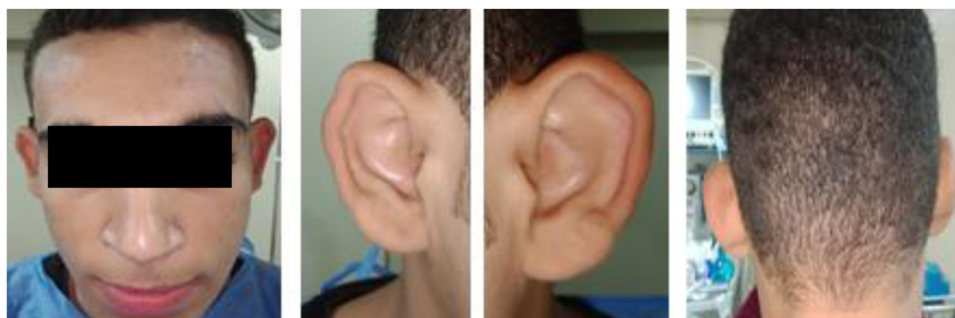There was no evidence of suture extrusion or pinpricking sensation of the sutures in any of the patients. Only one patient had a recurrence of the ear deformity.

Even though the patient satisfaction about the aesthetic results is the same in Tan et al.<sup>15</sup> retrospective study which compared Mustardé posterior suture technique with Stenstrom technique which adopt anterior cartilage scoring, the

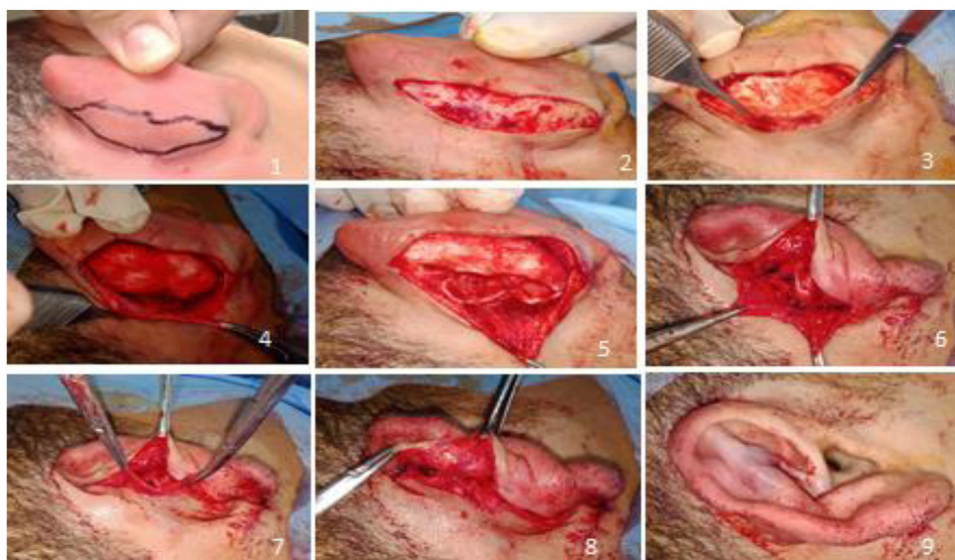**Table 4** measurement of helix-mastoid distance and concha-mastoid angles preoperative and postoperative.

Measurements	Helix-mastoid distance (mm)	Mean	SD/25-75th %	p-Value*
Preoperative	26-32	29.11	1-83	<0.001
Postoperative	14-20	17.22	1-79	
Measurements	Concha-mastoid angle (o)	Mean	SD/25-75th %	p-Value*
Preoperative	42-47	46.8	44-46	<0.006
Postoperative	24-27	25.6	24-25.5	

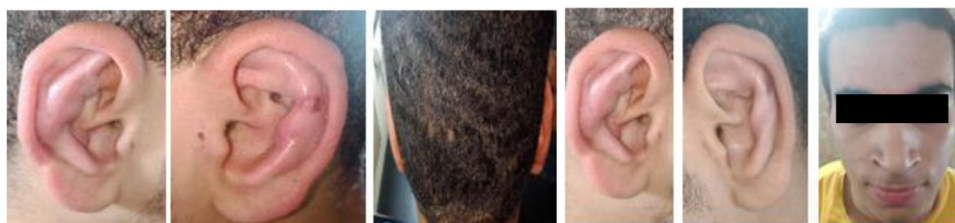\* Significant (p value less than 0.05).



**Preoperative frontal, side and back views**



**Intra operative steps**



**Early postoperative**

**Late postoperative**

**Figure 1** Case 1 in details. 1- Ellipse skin marking, 2- Skin de-epithelialization, 3- perichondrio-adipodermal flap, 4- perichondrio-adipodermal flap, 5- Conchal excision, 6- After repair, 7- Flap covering repair, 8- Flap covering repair, 9- Creation of antihelix.

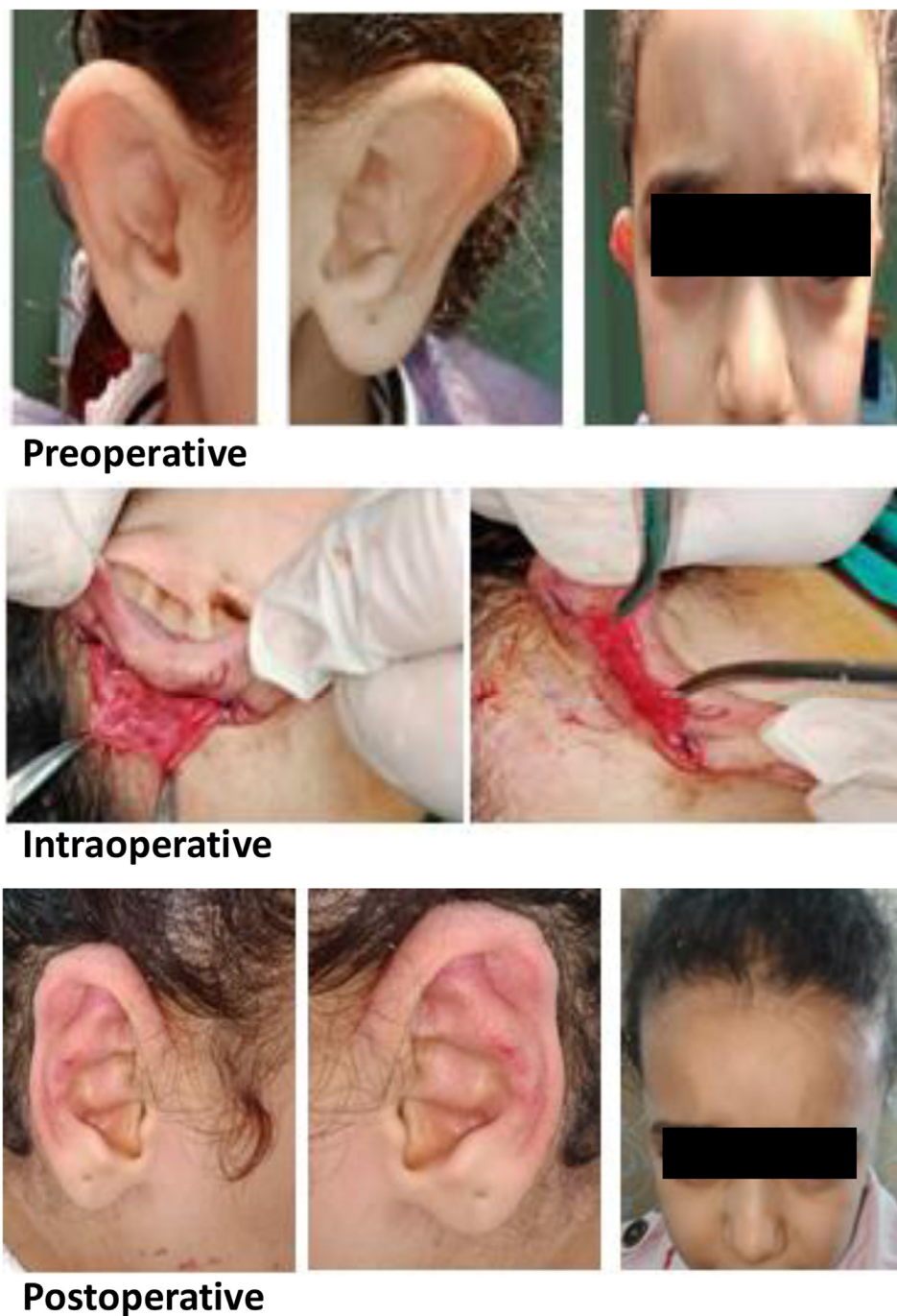

Figure 2 Case 2 in details.

ears that were operated with Mustardé method were reoperated twice more than the other method (24.4% compared with 9.9%). Tan has revealed that sinus formation and wound infection caused by suture extrusion were seen in 15% of the patients. Mustarde has published 2 studies. First, published in 1967, had 264 ears he had operated in a period of 10 years.<sup>19</sup> 17 patients had been not satisfied because of irregularities in the antihelix, sutures cutting through the cartilage, sinus formation, recurrence of the prominent ear deformity, and the increase in projection of lobule. In 1980, in the second study which done on 600 ears in 20-years

period, he reported a 0.01% sinus formation rate and 0.02% secondary operation rate without suture extrusion rate.<sup>20</sup>

Spira and Hardy<sup>21</sup> on the other hand, had discussed their experiences with Mustarde's approach, claiming that they did not get the same good results that minor complication rates were higher, and that partial recurrence rates were high.

In another study, Hyckel et al.<sup>22</sup> have compared Mustarde and Converse approaches and revealed that they could not find significant differences. Heftner<sup>23</sup> had measured patient satisfaction in the prominent ear

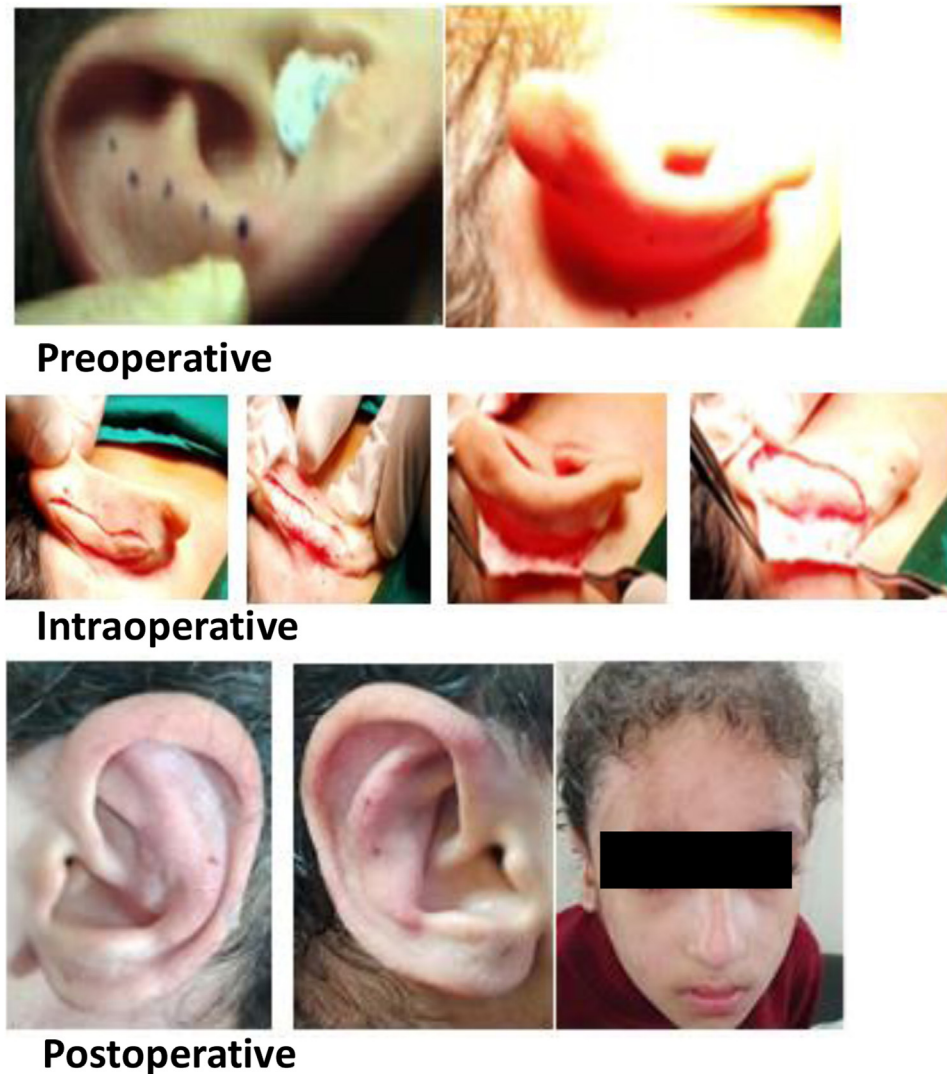

Figure 3 Case 3 in details.

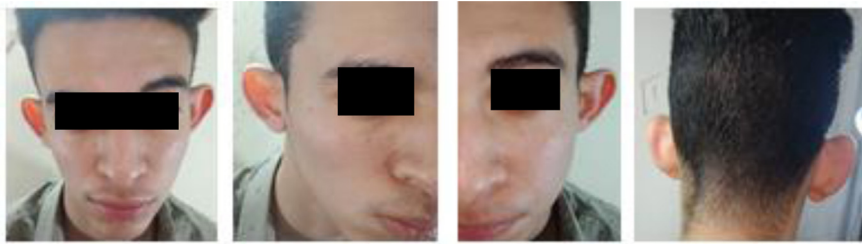surgery done with the Stenstrom technique and revealed that 89% of the patients were satisfied with the results. Heftner also stated that in 81% of the patients the Stenstrom technique had resulted in rounded and acceptable antihelical folds. In the 12-month follow-up period, Calder and Naasan<sup>24</sup> observed a 16.6% complication rate (infection, keloid development, hemorrhage, and anterior skin necrosis) and 8% recurrence rate.

There were no hematomas, skin necrosis, or other problems in any of our patients who had a medially based perichondrio-adipo-dermal flap. The absence of these problems can be explained by the fact that the anterior ear skin is not dissected from the subjacent cartilage, which means that the anterior skin circulation is not disrupted and the likelihood of hematoma formation is much reduced.

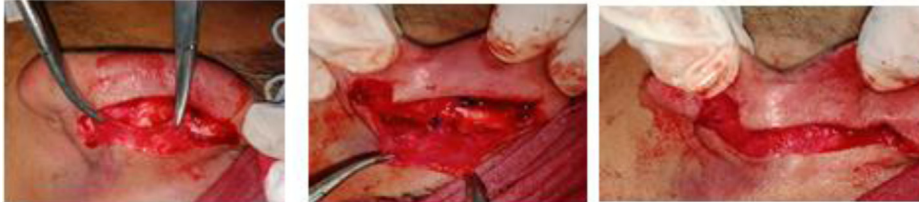After a 6-month follow-up period, Adamsson et al.<sup>12</sup> presented their conchal setback and antihelical suture

technique experiences in 119 ears, finding that patients operated with the cartilage-cutting approach had greater revision rates than those operated with the cartilage-sparing technique. They claimed that while there was not any recurrence in the mid and inferior one-thirds of the ear, they have observed a recurrence of 40% of in the superior one-third of the ear and this required a revision in 6.5% of the patients. Adamsson et al. suggested the addition of triangular fossa of the auricle to temporal fascia sutures to prevent this recurrence. An increase of 1–4 mm in the protrusion of the superior pole was found between the first and third months in controls of all the patients we have treated for the prominent ear deformity utilizing the distally based perichondrio-adipo-dermal flap. This supports overcorrection to overcome the chance of recurrence of the superior part of the ear.

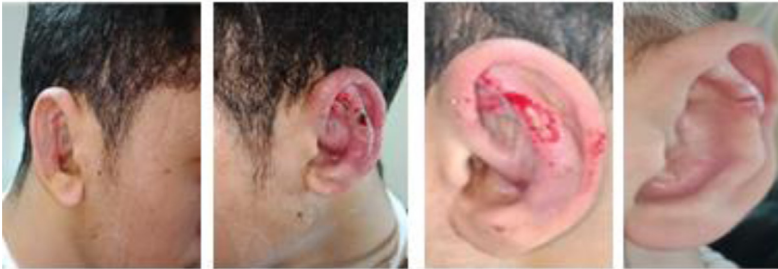



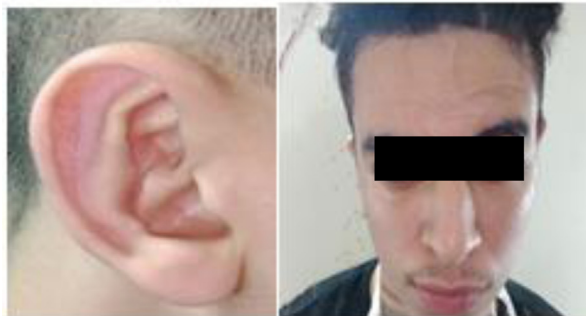**Preoperative**



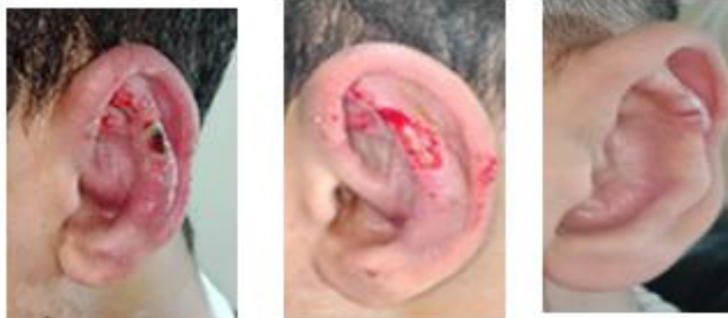**Intraoperative**



**Early postoperative**



**Late postoperative**



**Skin necrotic patch**

**After debridement**

**2<sup>nd</sup> intention healing**

**Figure 4** Case 4 in details.

## Conclusion

We may conclude that the medially based perichondrio-adipo-dermal flap approach was described as a simple and safe procedure that can be utilized in conjunction with the original method of repair to treat prominent ear deformities. The adoption of a medially based perichondrio-adipo-dermal flap covers the suture material while simultaneously providing the primary otoplasty technique with the flap's unique features, allowing the new shape to remain consistent throughout the post-operative period. We assume that the medially based perichondrio-adipo-dermal flap approach causes less tissue stress, reduces suture extrusion, and lowers recurrence rates because the suture lines are less tensioned due to cartilage memory, as the tension is shared between the suture and the dermal tissue. The flap will also fill the dead area between the cartilage and the postauricular skin, reducing the chance of hematoma formation.

Finally, the newly developed antihelical fold can be expected to have superior longevity as a result of new cartilage formation, which is caused by elevation of the perichondrium.

## Ethics approval

All procedures performed in the study involving human participants were in accordance with the ethical standards of our institutional research committee and with the 1964 Helsinki declaration and its later amendments or comparable ethical standards.

## Ethical considerations

### Ethics approval and consent to participate

Local ethical committee approval and Informed consent had been obtained before the onset of this study.

### Consent for publication

Not applicable.

### Availability of data and material

Data are available on request.

### Declaration of patient consent

The authors certify that they have obtained all appropriate patient consent forms, the patients signed informed consent regarding publishing their data and photographs in the journal.

## Funding

None.

## Conflicts of interest

The authors declare that no conflict of interest.

## References

1. Alexander KS, Stot DJ, Sivakumar B, Kang N. A morphometric study of the human ear. *J Plast Reconstr Aesthet Surg.* 2011;64:41–7.
2. Adamson PA, Litner JA. Otoplasty technique (review). *Facial Plast Surg Clin North Am.* 2006;14:79–87.
3. Ellis DAF, Kohane JD. A simplified approach to otoplasty. *J Otolaryngol.* 1992;21:66–9.
4. Hoehn JG, Ashruf S. Otoplasty: sequencing the operation for improved results. *Plast Reconstr Surg.* 2005;115:5e16.
5. Adamson JE, Hortox CE, Crawford HH. The growth pattern of the external ear. *Plast Reconstr Surg.* 1965;36:466–70.
6. Cho BC, Chung HY, Park JW. Surgical correction of prominent ear using modified tube technique and posterior approach. *J Craniofac Surg.* 2003;14:767–73.
7. Horlock N, Misra A, Gault DT. The post auricular fascial flap as an adjunct to Mustardee and Furnas type otoplasty. *Plast Reconstr Surg.* 2001;108:1487–90.
8. Hassanpour SE, Mosavizadeh SM. Posterior scoring of the scapha as a refinement in aesthetic otoplasty. *J Plast Reconstr Aesthet Surg.* 2010;63:78–86.
9. Gualdi A, Cambiaso-Daniel J, Gatti J, Wurzer P, Sljivich M, Scherer SS, et al. Double Triangular Cartilage Excision Otoplasty. *Plast Reconstr Surg.* 2018;141:348e–56e.
10. Alexander B, Thomas B, John MH. Revision otoplasty how to manage the disastrous. *Result Arch Facial Plast Surg.* 2012;14:205–10.
11. Kelly P, Holier L, Stal S. Otoplasty: evaluation, technique, and review. *J Craniofac Surg.* 2003;14:643–53.
12. Adamson PA, Litnr JA. Otoplasty technique (review). *Facial Plast Surg Clin North Am.* 2006;14:79–87.
13. Mustarde JC. Correction of prominent ears using buried mattress sutures. *Clin Plast Surg.* 1978;5:459.
14. Furnas DW. Correction of the prominent ears by concha mastoid sutures. *Plast Reconstr Surg.* 1968;42:189–93.
15. Tan K. Long-term survey of prominent ear surgery: a comparison of two methods. *Br J Plast Surg.* 1986;39:270–3.
16. Reynaud JP, Gary-Bobo A, Mateu J, et al. Chondrites postopératoires de l'oreille externe: 2 cases from a series of 200 cases (387 otoplasties). *Ann Chir Plast Esthet.* 1986;31:170.
17. Adamson PA. Complications of otoplasty. *Ear Nose Throat J.* 1985;64:568.
18. Bsat SO, Aksan T. New otoplasty approach: a laterally based post auricular dermal flap as an addition to mustarde and furnas to prevent sutures extrusions and recurrence. *Aesth Plast Surg.* 2014;38:83–9.
19. Mustardé JC. The treatment of prominent ears by buried mattress sutures: a ten-year survey. *Plast Reconstr Surg.* 1967;39:382.
20. Mustardé JC. Results of otoplasty by the author's method. In: Goldwyn RM, editor. Long-term results in plastic ed. *Reconstructive surgery.* Boston, MA: Little Brown; 1980. p. 139–44.
21. Spira M, Hardy SB. Mustardé otoplasty: a critical second look. In: Marchac D, Hueston JT, editors. *Transactions of the sixth international conference of plastic and reconstructive surgery.* Paris, France: Masson; 1975. p. 297–9.
22. Hyckle P, Schuman D, Mansel B. Method of converse for correction of prominent ears: comparison of results. *Acta Chir Plast.* 1990;32:164.
23. Hefner J. Follow-up study on B167 Stenstrom otoplasties. *Clin Plast Surg.* 1978;5:470.
24. Calder JC, Nasan A. Morbidity of otoplasty: a review of 562 consecutive cases. *Br J Plast Surg.* 1994;47:170.